

Editorial

Anatomical Distribution of Intramuscular Lipomas

N K Sferopoulos*

Department of Orthopaedics, "G. Gennimatas" Hospital, Thessaloniki, Greece

***Address for Correspondence:**

Dr. N.K.Sferopoulos, Department of Orthopaedics, "G. Gennimatas" Hospital, P. Papageorgiou 3, Thessaloniki, Greece, Tel: 00302310963270; Fax: 00302310968265; E-mail: sferopoulos@in.gr

Submitted: 04 April 2017**Approved:** 17 April 2017**Published:** 19 April 2017

Copyright: © 2017 Sferopoulos NK. This is an open access article distributed under the Creative Commons Attribution License, which permits unrestricted use, distribution, and reproduction in any medium, provided the original work is properly cited.

EDITORIAL

Lipomas are the most common type of soft tissue tumor occurring in the subcutaneous tissue. Rarely, lipomas present in the deep soft tissue such as intermuscular, intramuscular, and parosteal sites. When they occur within a skeletal muscle they are called intramuscular lipomas. Intramuscular lipomas may involve both children and adults. They are benign, nontender, deep located, circumscribed but unencapsulated lesions. Intramuscular lipomas account less than 1% of all lipomas. Most are located within a single muscle (solitary), while cases involving two or more muscles are very rare. They present with typical histological features. They may be divided into the infiltrative, the well-circumscribed and the mixed type. Differential diagnosis of the infiltrative type from liposarcoma is very difficult. Local recurrence may be evident if the surgical margin is not clear. They can occur in almost any anatomical site [1-15].

Intramuscular lipomas of the head may involve the tongue, which is one of the most commonly involved sites [16-24] or the tongue and the submandibular space [25]. They may also involve the cheek [26], the nose [27], the masseter [28] and the temporalis muscle [29,30]. In the eye the orbicularis oculi muscle and the eyelid [31], the superior oblique muscle [32], the superior rectus [33], the medial rectus in a child [34] have been involved.

Intramuscular lipomas of the neck [35] may be localized in the longus colli muscle [36], the platysma [14], the sternocleidomastoid muscle [37-40], the paraspinal muscles [41] and may be retropharyngeal or laryngeal infiltrating [42,43].

The chest wall [44,45] and the intercostal muscles [46] may also be involved. It may appear as a breast mass involving the pectoralis major [47-49] and may also involve the heart; involvement of the left ventricular myocardium, extending to the epicardial space; has also been reported [50]. The large muscles of the trunk may be involved such as the trapezius, the latissimus dorsi, the rhomboid major and the muscles of the anterior abdominal wall [14,51].

Intramuscular lipomas of the limbs may involve the thigh [52-54] and the shoulder [55], which are the most common locations [56-58]. The biceps brachii [59], the subscapularis [60], the deltoid [61-63], the supraspinatus [64,65], the infraspinatus [66] and the brachioradialis [67] may be involved, while localization adjacent to the proximal radius may be complicated by symptomatic radial nerve compression [68-70]. Involvement of the tensor fascia lata has also been reported [71] as well as of the vastus lateralis [51] and of the gluteus maximus and gastrocnemius [14].

Intramuscular lipomas of the hand and foot are rare. They may be associated with painful wrist triggering with associated carpal tunnel syndrome caused by an intramuscular lipoma of the lumbrical muscle [72,73]. They may be localized to the thenar [74-78], in the thenar or hypothenar muscles [79], to the abductor digiti minimi [80], to the extensors [81] and to the flexor hallucis brevis [82].

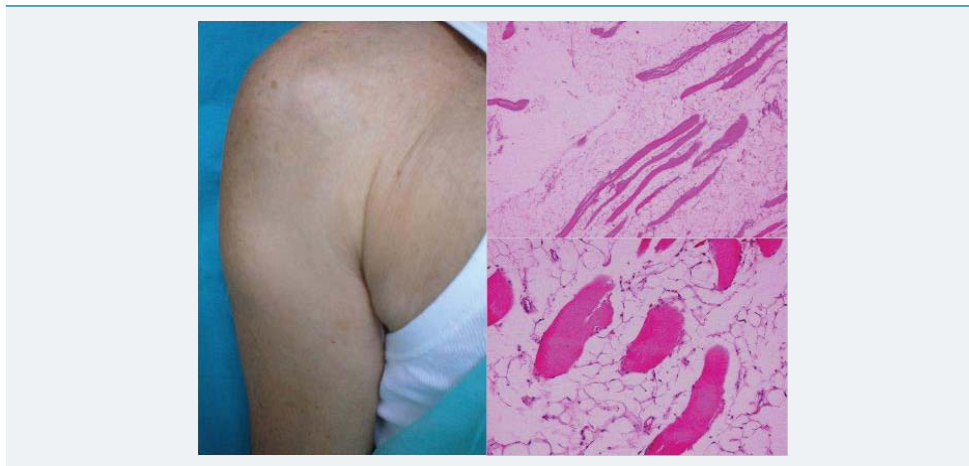


Figure 1: A 65-year-old man with an intramuscular lipoma of the long head of the triceps brachii muscle. Low-power and high-power views of the tumor showed mature fat cells between and among slightly atrophic skeletal muscle fibers.

REFERENCES

1. Bennhoff DF, Wood JW. Infiltrating lipomata of the head and neck. *Laryngoscope*. 1978; 88: 839-848. [Ref.: https://goo.gl/45orO9](https://goo.gl/45orO9)
2. Austin RM, Mack GR, Townsend CM, Lack EE. Infiltrating (intramuscular) lipomas and angioliipomas. A clinicopathologic study of six cases. *Arch Surg*. 1980; 115: 281-284. [Ref.: https://goo.gl/AJLW5I](https://goo.gl/AJLW5I)
3. Pollack S, Steinfeld AD. Radiographic diagnosis of intramuscular lipoma. *R I Med J*. 1984; 67: 129-130. [Ref.: https://goo.gl/Hb1bVf](https://goo.gl/Hb1bVf)
4. Caprio F, Lanza R, Amoroso L, Manzotti M, Cerioni M, et al. Computed tomographic findings and clinicopathologic features of intramuscular lipoma. *Rays*. 1985; 10: 39-42. [Ref.: https://goo.gl/ILjDZQ](https://goo.gl/ILjDZQ)
5. Fletcher CD, Martin-Bates E. Intramuscular and intermuscular lipoma: neglected diagnoses. *Histopathology*. 1988; 12: 275-287. [Ref.: https://goo.gl/udKU6x](https://goo.gl/udKU6x)
6. Harrington AC, Adnot J, Chesser RS. Infiltrating lipomas of the upper extremities. *J Dermatol Surg Oncol* 1990; 16: 834-837. [Ref.: https://goo.gl/kNvt08](https://goo.gl/kNvt08)
7. Schellong H, Falcone A, Günther M, Schmidt H. [Infiltrating intramuscular lipoma]. *Chirurg*. 1997; 68: 279-282. [Ref.: https://goo.gl/hESRDy](https://goo.gl/hESRDy)
8. Matsumoto K, Hukuda S, Ishizawa M, Chano T, Okabe H. MRI findings in intramuscular lipomas. *Skeletal Radiol*. 1999; 28: 145-152. [Ref.: https://goo.gl/v5cozv](https://goo.gl/v5cozv)
9. Allen B, Rader C, Babigian A. Giant lipomas of the upper extremity. *Can J Plast Surg*. 2007; 15: 141-144. [Ref.: https://goo.gl/qHrIkj](https://goo.gl/qHrIkj)
10. Bandeca MC, de Pádua JM, Nadalin MR, Ozório JE, Silva-Sousa YT, et al. Oral soft tissue lipomas: a case series. *J Canad Dental Assoc*. 2007; 73: 431-434. [Ref.: https://goo.gl/MRFWPR](https://goo.gl/MRFWPR)
11. Ott I, Sturm K, Losenhausen H, Issing PR. Intramuscular lipoma. A differential diagnosis of great prognostic relevance. *HNO*. 2009; 57: 1121-1125. [Ref.: https://goo.gl/xLWMQ7](https://goo.gl/xLWMQ7)
12. Su CH, Hung JK, Chang IL. Surgical treatment of intramuscular, infiltrating lipoma. *Int Surg* 2011; 96: 56-59. [Ref.: https://goo.gl/ela7FR](https://goo.gl/ela7FR)
13. Ramos-Pascua LR, Guerra-Álvarez OA, Sánchez-Herráez S, Izquierdo-García FM, Maderuelo-Fernández JÁ. Intramuscular lipomas: Large and deep benign lumps not to underestimated.

- Review of a series of 51 cases. *Rev Esp Cir Ortop Traumatol.* 2013; 57: 391-397. **Ref.:** <https://goo.gl/93THgM>
14. Han HH, Choi JY, Seo BF, Moon SH, Oh DY, et al. Treatment for intramuscular lipoma frequently confused with sarcoma: a 6 year retrospective study and literature review. *Biomed Res Int.* 2014. **Ref.:** <https://goo.gl/JKAB4u>
 15. McTighe S, Chernev I. Intramuscular lipoma: a review of the literature. *Orthop Rev (Pavia).* 2014; 6: 5618. **Ref.:** <https://goo.gl/1hK39Q>
 16. Garavaglia J, Gnepp D. Intramuscular (infiltrating) lipoma of the tongue. *Oral Surg Oral Med Oral Pathol.* 1987; 63: 348-350. **Ref.:** <https://goo.gl/g5jusy>
 17. Takeda Y. Intramuscular lipoma of the tongue: report of a rare case. *Ann Dent.* 1989; 48: 22-24. **Ref.:** <https://goo.gl/7SIFg5>
 18. Keskin G, Ustundag E, Ercin C. Multiple infiltrating lipomas of the tongue. *J Laryngol Otol.* 2002; 116: 395-397. **Ref.:** <https://goo.gl/B9Gu5k>
 19. Collela G, Lanza A, Rossiello L, Rossiello R. Infiltrating lipoma of the tongue. *Oral Oncology Extra.* 2004; 40: 33-35. **Ref.:** <https://goo.gl/6OM7n9>
 20. Akbulut M, Aksoy A, Bir F. Intramuscular lipoma of the tongue: a case report and review of the literature. *Aegean Pathol.* 2005; 2: 146-9. **Ref.:** <https://goo.gl/qjzgia>
 21. Chung JC, Ng RW. A huge tongue lipoma. *Otolaryngol Head Neck Surg.* 2007; 137: 830-831. **Ref.:** <https://goo.gl/USxjOI>
 22. Colella G, Biondi P, Caltabiano R, Vecchio GM, Amico P, et al. Giant intramuscular lipoma of the tongue: a case report and literature review. *Cases J.* 2009; 2: 7906. **Ref.:** <https://goo.gl/J24yj5>
 23. Garg M, Aggarwal R, Rajeev S. Intramuscular lipoma of tongue. *J Cutan Aesthet Surg.* 2011; 4: 152-153. **Ref.:** <https://goo.gl/X9xV8i>
 24. Amirzede A, Klaustermeyer W. Intramuscular lipoma of the tongue masquerading as angioedema. *Ear, Nose Throat J.* 2013; 92: E4-E5. **Ref.:** <https://goo.gl/Z6jQ08>
 25. Dattilo DJ, Ige JT, Nwana EJ. Intraoral lipoma of the tongue and submandibular space: report of a case. *J Oral Maxillofac Surg.* 1996; 54: 915-917. **Ref.:** <https://goo.gl/j0dCmP>
 26. Piattelli A, Fioroni M, Rubini C. Intramuscular lipoma of the cheek: a case report. *J Oral Maxillofac Surg.* 2000; 58: 817-819. **Ref.:** <https://goo.gl/PclYJX>
 27. Vincent J, Baker P, Grischkan J, Fernandez Faith E. Subcutaneous midline nasal mass in an infant due to an intramuscular lipoma. *Pediatr Dermatol.* 2017. **Ref.:** <https://goo.gl/FZley9>
 28. Tsumuraya G, Yamada H, Shimizu H, Hamada Y. Intramuscular lipoma in the masseter muscle: a case report. *Br J Oral Maxillofac Surg.* 2014; 52: e21-e23. **Ref.:** <https://goo.gl/OjsN5A>
 29. Uemura T, Suse T, Yokoyama T, Mitsukawa N, Yoshikawa A. Intramuscular benign lipoma of the temporalis muscle. *Scand J Plast Reconstr Surg Hand Surg.* 2002; 36: 231-234. **Ref.:** <https://goo.gl/OXGcYf>
 30. Ban M, Kitajima Y. Intramuscular lipoma within the temporal muscle. *Int J Dermatol.* 2002; 41: 689-690. **Ref.:** <https://goo.gl/mDFW00>
 31. Charles NC, Palu RN. Intramuscular lipoma of the eyelid. *Ophthalmic Surg Lasers.* 2000; 31: 340-341. **Ref.:** <https://goo.gl/HkxLza>
 32. Dutton J, Wright J. Intramuscular lipoma of the superior oblique muscle. *Orbit.* 2006; 25: 227-233. **Ref.:** <https://goo.gl/bIEvRT>
 33. Hristodulopulos V, Medel R. Intramuscular lipoma of superior rectus muscle. *Ophthal Plast Reconstr Surg.* 2016; 32: e52-e55. **Ref.:** <https://goo.gl/E88v0k>
 34. Shiraki K, Kamo M, Sai T, Kamo R. Rare site for an intramuscular lipoma. *Lancet.* 2002; 359: 2077. **Ref.:** <https://goo.gl/E5PqSU>
 35. Lerosey Y, Choussy O, Gruyer X, François A, Marie JP, et al. Infiltrating lipoma of the head and neck: a report of one pediatric case. *Int J Pediatr Otorhinolaryngol.* 1999; 47: 91-95. **Ref.:** <https://goo.gl/cUvk54>
 36. Pichiéri A, Marotta N, Raco A, Delfini R. Intramuscular infiltrating lipoma of the longus colli muscle: a very rare cause of neck structures compression. *Cent Eur Neurosurg.* 2010; 71: 157-159. **Ref.:** <https://goo.gl/xtwfqj>

37. Mattel SF, Persky MS. Infiltrating lipoma of the sternocleidomastoid muscle. *Laryngoscope* 1983; 93: 205-207. **Ref.:** <https://goo.gl/XRPbEV>
38. Moumoulidis I, Durvasula P, Jani P. Well-circumscribed intramuscular lipoma of the sternocleidomastoid muscle. *Auris Nasus Larynx*. 2004; 31: 283-285. **Ref.:** <https://goo.gl/AoYRQ0>
39. Ozcan C, Gorur K, Talas D, Aydin O. Intramuscular benign lipoma of the sternocleidomastoid muscle: a rare cause of neck mass. *Eur Arch Otorhinolaryngol*. 2005; 262: 148-150. **Ref.:** <https://goo.gl/cq3chV>
40. Sohn W, Kim JH, Jung SN, Kwon H, Cho KJ. Intramuscular lipoma of the sternocleidomastoid muscle. *J Craniofacial Surg*. 2010; 21: 1976-1978. **Ref.:** <https://goo.gl/XdMKNb>
41. Dattolo RA, Nesbit GM, Kelly KE, Cupp CL. Infiltrating intramuscular lipoma of the paraspinal muscles. *Ann Otol Rhinol Laryngol*. 1995; 104: 582-584. **Ref.:** <https://goo.gl/zqOgQ0>
42. Senchenkov A, Werning J, Staren E. Radiographic assessment of the infiltrating retropharyngeal lipoma. *Otolaryngol Head Neck Surg*. 2001; 125: 658-660. **Ref.:** <https://goo.gl/da7kQ3>
43. Deschler DG, Lee K, Tami TA. Laryngeal infiltrating intramuscular lipoma. *Otolaryngol Head Neck Surg*. 1993; 108: 374-377. **Ref.:** <https://goo.gl/s3F6HK>
44. Takamori S, Miwa K, Hayashi A, Shirouzu K. Intramuscular lipoma in the chest wall. *Eur J Cardiothorac Surg*. 2004; 26: 1038. **Ref.:** <https://goo.gl/AWOfdz>
45. Lee JH, Do HD, Lee JC. Well-circumscribed type of intramuscular lipoma in the chest wall. *J Cardiothorac Surg*. 2013; 8: 181. **Ref.:** <https://goo.gl/DtFCqE>
46. Hwang J, Jo WM, Min BJ, Shin JS. Deep-seated intramuscular lipoma penetrates the intercostal muscle. *J Thorac Dis*. 2015; 7: E493-E495. **Ref.:** <https://goo.gl/Mkm2BS>
47. Gopal U, Patel MH, Wadhwa MK. Intramuscular lipoma of the pectoralis major muscle. *J Postgraduate Med*. 2002; 48: 330-331. **Ref.:** <https://goo.gl/VP7V4B>
48. Pant R, Poh ACC, Hwang SG. An unusual case of an intramuscular lipoma of the pectoralis major muscle simulating a malignant breast mass. *Annals Academy of Medicine Singapore*. 2005; 34: 275-276. **Ref.:** <https://goo.gl/Q2XzC9>
49. D'Alfonso TM, Shin SJ. Intramuscular lipoma arising within the pectoralis major muscle presenting as a radiographically detected breast mass. *Arch Pathol Lab Med*. 2011; 135: 1061-1063. **Ref.:** <https://goo.gl/uvkeCU>
50. Oyama N, Oyama N, Komatsu H, Okita K, Yonezawa K, et al. Left ventricular asynchrony caused by an intramuscular lipoma: computed tomographic and magnetic resonance detection. *Circulation*. 2003; 107: e200-e2001. **Ref.:** <https://goo.gl/DwEMOG>
51. Kindblom LG, Angervall L, Stener B, Wickbom I. Intermuscular and intramuscular lipomas and hibernomas. A clinical, roentgenologic, histologic, and prognostic study of 46 cases. *Cancer*. 1974; 33: 754-762. **Ref.:** <https://goo.gl/FyWSPj>
52. Bjerregaard P, Hagen K, Daugaard S, Kofoed H. Intramuscular lipoma of the lower limb. Long-term follow-up after local resection. *J Bone Joint Surg Br*. 1989; 71: 812-815. **Ref.:** <https://goo.gl/hlP8le>
53. Gutknecht DR. Painful intramuscular lipoma of the thigh. *South Med J*. 2004; 97: 1121-1122. **Ref.:** <https://goo.gl/UixNvt>
54. Ezirmik N, Yildiz K. Deep intramuscular lipoma in thigh. *Med J Bakirkoy*. 2011; 7: 167-169.
55. Grandbois L, Vade A, Lim-Dunham J, Al-Masri H. MRI findings of an intermuscular lipoma in a 2-year-old. *Pediatr Radiol*. 2006; 36: 974-976. **Ref.:** <https://goo.gl/X8iVSV>
56. Kransdorf MJ, Bancroft LW, Peterson JJ, Murphey MD, Foster WC, et al. Imaging of fatty tumors: distinction of lipoma and well-differentiated liposarcoma. *Radiology*. 2002; 224: 99-104. **Ref.:** <https://goo.gl/k3DgcW>
57. Bassett MD, Schuetze SM, Distèche C, Norwood TH, Swisshelm K, et al. Deep-seated, well-differentiated lipomatous tumors of the chest wall and extremities. The role of cytogenetics in classification and prognostication. *Cancer*. 2005; 103: 409-416. **Ref.:** <https://goo.gl/6cVVKA>
58. Nishida J, Morita T, Ogose A, Okada K, Kakizaki H, et al. Imaging characteristics of deep-seated lipomatous tumors: intramuscular lipoma, intermuscular lipoma, and lipoma-like liposarcoma. *J Orthop Sci*. 2007; 12: 533-541. **Ref.:** <https://goo.gl/2pG6Ap>
59. Lahrach K, el Kadi KI, Mezzani A, Marzouki A, Boutayeb F. An unusual case of an intramuscular lipoma of the biceps brachii. *Pan African Med J*. 2013; 15: 40. **Ref.:** <https://goo.gl/2VHSgu>

60. Balabram D, Cabral CC, Filho OdeP, Barros CP. Intramuscular lipoma of the subscapularis muscle. *Sao Paulo Med J.* 2014; 132: 65-67. **Ref.:** <https://goo.gl/YH22uD>
61. Warner JJ, Madsen N, Gerber C. Intramuscular lipoma of the deltoid causing shoulder pain: report of two cases. *Clin Orthop Relat Res.* 1990; 253: 110-112. **Ref.:** <https://goo.gl/vdC7jm>
62. Ramos Pascua L, Alonso León A, Santos Sánchez JA, Ferrández Portal L. Intramuscular lipoma of the deltoid mimicking a sarcoma. A case report. *Chir Organi Mov.* 2001; 86: 153-157. **Ref.:** <https://goo.gl/DxtQvg>
63. Kapetanakis S, Papatthanasiou J, Dermon A, Dimitrakopoulou A, Ververidis A, et al. Unusual intramuscular lipoma of the deltoid muscle. *Folia Med.* 2010; 52: 68-71. **Ref.:** <https://goo.gl/3w1kx5>
64. Egea Martinez JM, Mena JF. Lipoma of the supraspinatus muscle causing impingement syndrome a case report. *J Shoulder Elbow Surg.* 2009; 18: 3-5. **Ref.:** <https://goo.gl/nLNTVG>
65. Ferrari L, Haynes P, Mack J, DiFelice GS. Intramuscular lipoma of the supraspinatus causing impingement syndrome. *Orthopedics* 2009; 32: 601. **Ref.:** <https://goo.gl/3AwjK>
66. Sungur N, Kiliç H, Ozdemir R, Sensöz O. An infiltrating intramuscular lipoma of the brachioradialis muscle. *Ann Plast Surg.* 2001; 46: 353-354. **Ref.:** <https://goo.gl/2GqsxT>
67. Coraci D, Santilli V, Padua L. Painful Intramuscular Lipoma of the Infraspinatus: Unusual Location and Presentation. *Orthopedics.* 2016; 39: 206. **Ref.:** <https://goo.gl/B8eyVO>
68. Cappellini O. A case of dissociated paralysis of the radial nerve caused by intramuscular lipoma. *Chir Organi Mov.* 1958; 45: 338-343. **Ref.:** <https://goo.gl/CMvl0k>
69. Manes E. On a case of dissociated paralysis of the radial nerve caused by intramuscular lipoma. *Osp Ital Chir.* 1968; 19: 165-172. **Ref.:** <https://goo.gl/OdNYnB>
70. Allagui M, Maghrebi S, Touati B, Koubaa M, Hadhri R, et al. Posterior interosseous nerve syndrome due to intramuscular lipoma. *Eur Orthop Traumatol.* 2014; 5: 75-79. **Ref.:** <https://goo.gl/oO4eie>
71. Feng A, Igolnikov I, Brown CH, Weinik MM. Poster 197-E Hip Pain Secondary to Intramuscular Lipoma of Tensor Fascia Lata: A Case Report. *PM R.* 2016; 8: S329-S330. **Ref.:** <https://goo.gl/ct6reN>
72. Cossey AJ, Stranks GJ. Intramuscular lipoma in an anomalous muscle belly of the middle finger lumbrical as a cause of carpal tunnel syndrome and trigger wrist. *Orthopedics.* 2003; 26: 85-86. **Ref.:** <https://goo.gl/xAeGS0>
73. Berlund P, Kalamaras M. A case report of trigger wrist associated with carpal tunnel syndrome caused by an intramuscular lipoma. *Hand Surg.* 2014; 19: 237-239. **Ref.:** <https://goo.gl/yUtJ5Z>
74. Aldredge WM, Halpert B. Lipoma of the thenar. *Surgery.* 1948; 24: 853. **Ref.:** <https://goo.gl/Xpx8hs>
75. Zamora MA, Zamora CA, Samayoa EA, Morales HA, Ceballos JF. High-resolution ultrasonography in an aggressive thenar intramuscular lipoma. *J Ultrasound Med.* 2005; 24: 1151-1155. **Ref.:** <https://goo.gl/9sCYKU>
76. Mohan L, Semoes J. Thenar intramuscular lipoma: an unusual case. *Internet J Surg.* 2008; 17:1-3. **Ref.:** <https://goo.gl/Jl17JE>
77. Chernev I, Tingey S. Thenar intramuscular lipoma: A case report. *J Med Cases.* 2013; 4: 676-678. **Ref.:** <https://goo.gl/XGlfjg>
78. Papakostas T, Tsovilis AE, Pakos EE. Intramuscular lipoma of the thenar: A Rare Case. *Arch Bone Jt Surg.* 2016; 4: 80-82. **Ref.:** <https://goo.gl/cwB00v>
79. Lee YH, Jung JM, Baek GH, Chung MS. Intramuscular lipoma in thenar or hypothenar muscles. *Hand Surg.* 2004; 9: 49-54. **Ref.:** <https://goo.gl/EdOM1t>
80. Lui TH. Intramuscular lipoma of abductor digiti minimi mimicking intramuscular haemangioma. *BMJ Case Rep.* 2013. **Ref.:** <https://goo.gl/f0nDgL>
81. Rispoli L, Singh JR, Piesco J. Unusual location of intramuscular lipoma presenting as an extensor tendon tear: A diagnostic dilemma. *Am J Phys Med Rehabil.* 2017. **Ref.:** <https://goo.gl/opvxXy>
82. Kalmar G, Doobay N. Intramuscular lipoma of the flexor hallucis brevis muscle. A case report. *J Am Podiatr Med Assoc.* 2017; 107: 80-84. **Ref.:** <https://goo.gl/ftLjS>